



PATIENT

Moose Lepow

SPECIES

Canine

BREED

Chihuahua Mix

SEX

Male Neutered

AGE

12 years

WEIGHT

14.2lbs

INTERPRETED BY

Maggie Machen Lamy,
DVM, DACVIM
(Cardiology)

IMAGING PERFORMED BY

Shari Reffi, CVT

HOSPITAL NAME

Newton Veterinary
Hospital

REFERRING VET

Dr. Kim

INVOICE

22667

DATE

2/17/22

PRESENTING CLINICAL SIGNS

History: Grade IV/VI murmur, coughing.

-Current medications: Pimobendan 5mg 1/4-tab q24h, Enalapril 2.5mg q12h.

-Abnormal PE/Chem/CBC/UA Results: Phos 5.2, Albumin 4.3, ALP 177.

ECHOCARDIOGRAM FINDINGS

2D, m-mode and Doppler imaging are available. Diffuse thickening of mitral valve leaflets (anterior > posterior) with significant prolapse into the left atrial lumen. Flail leaflet with suspicion for a ruptured chordae tendineae. Severe eccentric mitral regurgitation with severe left atrial dilation. Significant LV dilation with depressed myocardial function. The tricuspid valve appears mildly thickened, with mild tricuspid regurgitation. Mild right heart enlargement. The pulmonic and aortic valves are normal in morphology and mobility. Normal pulmonic and aortic outflow velocities. No pulmonic or aortic insufficiency. No pericardial or pleural effusion noted. No cardiac tumors observed.

CARDIAC CHART

CANINE CARDIAC PARAMETERS	MR VMAX (m/s)	TR VMAX (m/s)	LA/AO (Boon method)	LA/AO (Heart Base; Swe)	FS (%)	EF (%)	EPSS (cm)
NORMAL PARAMETER	4.5-5.5	<2.7	1.3	<1.6	28-40	40-100	<0.6
PATIENT	5.1	NM	2.0	2.1	22	40	0.49
CANINE CARDIAC PARAMETERS	HR (BPM)	AV VMAX (m/s)	PV MAX (m/s)	BODY WEIGHT (kg)	LA 2D short axis Base view (cm)	LVIDd Avg; 2D and m-mode short axis (cm)	LVIDs Avg; 2D and m-mode short axis (cm)
NORMAL PARAMETER	50-100	0.7-1.7	0.7-1.6	BELOW	BELOW	BELOW	BELOW
PATIENT	200	1.0	0.9	6.4	2.6	4.1	3.2
*Normal chamber parameters expressed as a mean value (SD)				3	1.27 (5.3)	2.46 (2.46)	1.36 (5.5)
BODY WEIGHT DEPENDENT PARAMETERS				5	1.40 (4.5)	2.74 (5.2)	1.60 (4.7)
<i>*Note: All measurements based upon multi-modal images and methods. An average value is reported.</i>				10	1.50 (3.8)	3.27 (3.5)	2.06 (3.1)
				15	1.83 (2.0)	3.71 (2.4)	2.43 (2.1)
				20	2.02 (1.9)	4.14 (2.2)	2.80 (2.0)
				25	2.18 (2.4)	4.48 (2.9)	3.10 (2.5)
				30	2.33 (3.3)	4.83 (3.9)	3.39 (3.4)
				35	2.48 (4.3)	5.17 (5.0)	3.69 (4.5)
				40	2.62 (5.2)	5.48 (6.1)	3.96 (5.4)
				50	2.88 (7.1)	6.07 (8.3)	4.46 (7.4)

Adapted from June Boon, Veterinary Echocardiography, 1998
Rishniw M and Hollis NE, J Vet Intern Med 2000; 14:429-435
Hansson et al, Vet Rad and Ultrasound 2002
Bonagura et al. Echocardiography: principles of interpretation, Vet Clin North Am 15:1177, 1995

INTERPRETATION OF THE FINDINGS & FURTHER RECOMMENDATIONS

The cause of the murmur is chronic degenerative valve disease causing severe mitral and mild tricuspid regurgitation. Severe left atrial enlargement indicates the risk for spontaneous congestive heart failure is elevated. A ruptured chordae is visualized which dramatically raises this risk. Mild TR is also noted, with suspicion for early pulmonary hypertension. No additional issues such as systolic dysfunction are identified.

The described cough is likely multi-factorial in origin, including a mechanical component due to cardiomegaly, possible concurrent airway disease and/or early CHF given the severity of disease.



PATIENT

Moose Lepow

SPECIES

Canine

BREED

Chihuahua Mix

SEX

Male Neutered

AGE

12 years

WEIGHT

14.2lbs

INTERPRETED BY

Maggie Machen Lamy,
DVM, DACVIM
(Cardiology)

IMAGING PERFORMED BY

Shari Reffi, CVT

HOSPITAL NAME

Newton Veterinary
Hospital

REFERRING VET

Dr. Kim

INVOICE

22667

DATE

2/17/22

Screening chest radiographs are recommended. Given the symptoms and echo findings, full lifelong cardiac support is recommended as below including Lasix therapy. Depending on clinical response to the medications, cough suppression may also be useful. Monitoring of sleeping breathing rates in the future will be paramount to determine the origin of any future cough. The average survival of canine patients with active pulmonary edema is 8-9 months on medications, however they generally are able to maintain a good quality of life for that period. Patient will always be at risk for recurrent CHF, development of arrhythmias/LA tear, syncope and/or sudden death in the future. Monitoring of renal values is recommended lifelong.

Omega fatty acid supplementation and mild salt restriction may also be of some long-term benefit. Monitor for development of a worsening cough, labored breathing, exercise intolerance or collapse episodes.

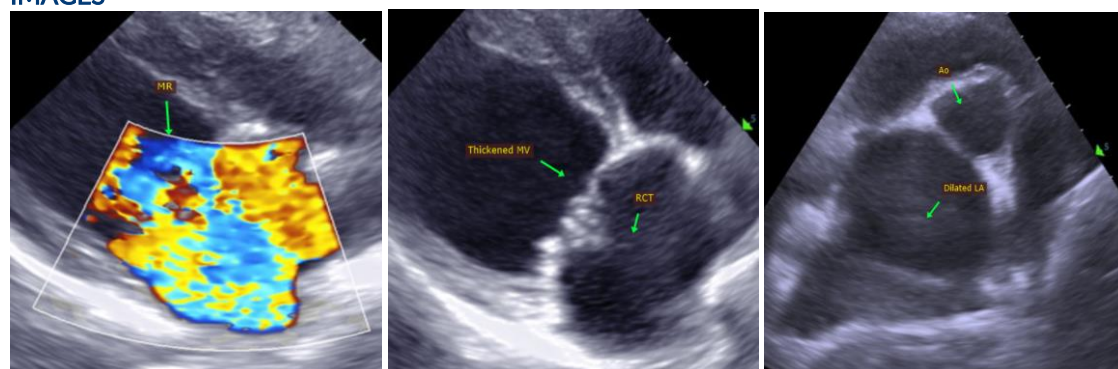
PLAN

Screening BP is recommended. Administer Pimobendan 0.3mg/kg PO q12h. Administer low dose furosemide/Lasix 1 mg/kg PO q12h. Administer spironolactone 1-2mg/kg PO q12h. Consider hydrocodone with homatropine (0.2-0.4mg/kg PO up to q4-6 hours PRN) if cough persists despite normal SRRs.

A renal panel and BP are recommended in 10-14 days, then every 3-4 months on diuretics to ensure tolerance of medications. If doing well at that time and BP >130mmHg, institute ACEI 0.5mg/kg PO q12h.

A recheck echocardiogram is recommended in 6 months to screen for progression, sooner if clinical signs arise/persist.

IMAGES



The information and recommendations provided are based on the images presented by the referring veterinarian. No evaluation can be communicated regarding pathology that was not visible in the image/video clips provided.

Thank you for this referral. This report was generated using transcription software, and minor dictation errors may be present. If the clinical or image interpretation does not parallel your findings or if I can be of any further assistance, please contact me.

Maggie Machen Lamy, DVM
Diplomate of the American College of Veterinary Internal Medicine (Cardiology)
info@sonopath.com